

## SAMPLE DIAGRAMS OF ZONE CONCEPT

K. Jean Cotterman RNC-E, IBCLC

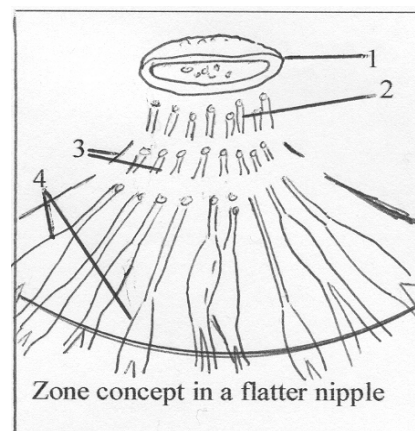
### ZONE ONE

The skin (composed of keratinizing squamous epithelium, flat and protective scale-like cells). These extend completely down inside to line the galactophores, which travel through the center of the mamilla. Includes the dermal layer with circulatory and lymph capillaries and nerves. (Imagine this zone 'shaped like a 'thimble')

### ZONE TWO

The internal flesh of the mamilla is devoid of fatty tissue.. Includes intertwined circular and radial muscles, sebaceous glands, and connective tissue plus lymphatic and circulatory capillaries, elastic fibers, nerves, and the galactophores, as described above.

(Imagine this zone as 'the contents of that thimble')

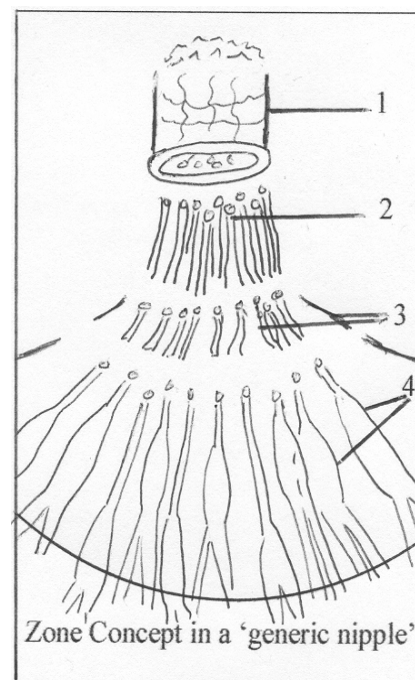


### ZONE THREE

The nipple "root" or base of the nipple, at its junction with the visible areola. There is no fat here, making the skin closer to the deep subnipple connective tissue and ducts within this zone. This allows efficient extrusion. This zone also includes radial and circular muscles, lymphatic and circulatory vessels, nerves and elastic fibers. Within this zone, the galactophores end as the cellular lining changes abruptly from keratinizing squamous epithelial to cuboidal cells like those lining all other mammary ducts. (Imagine cells that can 'reshape like marshmallows'.)

### ZONE FOUR

The external areola with its circular and radial muscles, plus the subareolar connective tissue, (without fat). Includes nerves, lymphatic and circulatory capillaries, deep central subnipple ducts, and the lumen and walls of the milk sinuses, which are lined with cuboidal cells. Most are surrounded by myoepithelial cells. They have a solid wall of elastic tissue around them. In the resting breast, they are up to 3 mm. wide on ultrasound, and appear "accordion-pleated" under the microscope. Some compression and extrusion occur here.



References:

Hughes ESR. The Development of the Mammary Gland, *Annals of the Royal College of Surgeons*, Oct. 25, 1949 pp. 99-119.

Montagna W, Macpherson E, Some Neglected Aspects of the Anatomy of Human Breasts, *Journ Inv Derm*, July 1974, Vol 63;1: p. 10-16.

Stevens A, Lowe JS, *Human Histology*, 2<sup>nd</sup> edition, Mosby Co., London, Baltimore, 1997.

Rizzato G, Chersivani R, Macorig D, Perrone R, *Dynamic Breast Anatomy*  
<http://www.liveto.com/semi/sonic/pdf/se01.pdf>